

CASE STUDY

Reduction of Vertebral Subluxation using Torque Release Technique with Changes in Fertility: Two Case Reports

Elizabeth Anderson-Peacock, DC, DICCP

ABSTRACT

Objective: This article offers a description of two women who presented with varying complaints to a family-based chiropractic practice. In each case one of the complaints was infertility.

Clinical Features: In both case histories, the women had been deemed medically infertile and artificial insemination was being considered. Upon presentation, complete chiropractic evaluations were performed which detected spinal subluxations.

Chiropractic Care and Outcome: Torque Release Technique Protocols were utilized for both evaluation and application of care. Adjustments were performed with an

instrument, the Integrator, to improve spinal-neural integrity. During the course of chiropractic care both women were able to conceive.

Conclusion: Although chiropractic care is not a treatment for infertility, it is postulated that improvement of spinal neural integrity through specific chiropractic adjustments may have contributed to improved homeostasis and physiological adaptation thus allowing the body to express a greater level of health as an outcome. Various effects via the reduction of the vertebral subluxation complex are postulated.

Key words: *Chiropractic, Infertility, Torque Release technique, Vertebral Subluxation*

Introduction

Infertility is a condition of the reproductive system whereby there is either an inability to conceive or an inability to carry a pregnancy to term after one year of unprotected intercourse.

Approximately 40 percent of the time infertility is due to problems with the female, 40 percent of the time due to problems with the male and approximately 20 percent of the time it is due to problems in both partners or remains unexplained.

Anecdotal evidence has been presented on cases of infertility within chiropractic such that when the reduction of the subluxation has occurred or when improvement of function has occurred the bodies response changes.^{1,2,3}

The purpose of chiropractic is to optimize health. Chiropractic utilizes the principle that the body's innate recuperative power is affected by and integrates through the nervous system. Chiropractic practice focuses on the relationship between structure (primarily of the spine) and function (as coordinated by the nervous system) and how that relationship affects the preservation and restoration of health.⁴ Traditionally, causes of interference or dysfunction can be grouped into three main categories: trauma (macro and micro), toxicity (chemical changes) and autosuggestion (thoughts/stress).⁵

Chiropractors recognize that there may be long reaching effects within the function of the body as a bi-product of restoration of biomechanical and neurological integrity.

Chiropractors have traditionally restored homeostasis within the body by the detection and reduction of the vertebral subluxation.

A subluxation as defined by the Association of Chiropractic Colleges is a complex of functional and/or structural and/or pathological articular changes that compromise neural integrity and may influence organ system function and general health. In addition a subluxation is evaluated, diagnosed, and managed through the use of chiropractic procedures based on the best available rational and empirical evidence.⁴

This paper cites two examples of outcomes in infertile women who while undergoing chiropractic care, became pregnant and sustained their pregnancy, one with a 6 week premature infant and the other to term.

Clinical Features

Case One

In case study one, a 35 year old Caucasian female presented with a chief complaint of chronic recurrent low back pain of five years duration. It was described as moderate to severe pain with varying character ranging from ache to sharp to throbbing

Dr. Elizabeth Anderson-Peacock, Private Practice
300 Lakeshore Drive, Suite 202, Barrie, ON, Canada L4N 0B4

located at the sacrum to the lower lumbar spine midline. Occasional paresthesia was noted into the left postero-lateral leg and this had extended to the ankle.

Aggravating factors were gardening, carrying anything heavy and stress. The patient gave the example that shoveling snow for 15 minutes would cause her to be bent over in extreme pain. During exacerbations, a heaviness was noted in both legs. Nothing improved the pain once exacerbated and she tried to avoid aggravating factors.

The initial onset of low back pain was subsequent to a fall whereby she landed on a rock and fractured her sacrum. She was hospitalized for this injury. The intensity of this trauma subsided and reached a plateau approximately three years prior. Her symptoms for the past two years were constantly present at a low grade level plus additional episodes of acute exacerbations. She described her low back symptoms as getting neither better or worse for the past three years.

She noted that she had been trying to conceive for two years and was considering artificial insemination. She had a son who was three at the time of her presentation to this office.

Secondary complaints were that of recurrent neck pain and stiffness aggravated by stress for which she described having for years. Occasional paresthesia into the left hand was noted without pattern. She noted chronic insomnia with resultant fatigue, irritability and reduced concentration. Additional complaints were chronic constipation. She had a past history of smoking for which she quit and occasional intake of alcohol. She tried to exercise about four times per week. She had explained she was under a great deal of stress with her husband traveling out of country much of the time.

Medication had just begun with Paxil. No family history was available as she was adopted. Previous surgeries involved a fusion of her fourth and fifth digits of the right foot when she was about 15 years old. She felt she compensated her gait due to pain in the fourth and fifth metatarsal region.

The examination noted a height at 5'6" and weight of 137 pounds. Postural examination revealed unleveling in the PA posture with the right occiput, shoulder girdle and pelvis held superior when compared to the left.

Six directions in ranges of motion (ROM) were performed in the cervical, thoracic and lumbar spine (Flexion, extension, lateral bending left and right and rotation left and right). Gross passive ROMs were diminished with cervical flexion by 10% and left rotation by 5%. Thoracic-lumbar ROMs were reduced in extension by 20% with pain elicited from L2-L5 midline which extended bilateral to the erector spinae (left greater than the right). Cervical and Lumbar axial compression test and compression with extension and rotation test (Kemps) were within normal limits. Resisted muscle testing in the upper and lower limbs were within normal limits. Deep tendon reflexes and sensation to pinwheel in the upper and lower limb were within normal limits. Orthopedic tests of straight leg raising, knee to chest and Fabre Patrick were unremarkable.

Sensitivity was noted beneath the right fourth and fifth metatarsal heads. Segmental palpation of the vertebral areas noted a loss of the normal joint play at C2-3 and C5 on the right, T3-4 on the left, T8-9 bilateral, L3-4 on the right and L5- sacrum bilateral.

Initial Tonal evidence of spinal stress was noted with a prone leg length check according to TRT protocol as a positive left cervical syndrome and negative right Derifield. While prone bilateral Achilles were graded as moderately hypertonic. Computerized Thermography and Surface Electromyography was performed according to the protocols of the Insight 7000 Subluxation Station with abnormal heat generated in the Thermography at the levels of C6, T9 and T12. Surface EMG noted on a 50uv scale increased tone in the paraspinal musculature throughout the spine at multiple levels with asymmetry maximized at the cervico-thoracic and thoraco-lumbar regions.

X-rays were performed with views of an AP full spine, Lateral cervical and lumbar spine. On the AP a mild translation from T6 left to T9 right was noted. A right open disc wedge was noted at T9-10 with T9 vertebral body superior on the right. The lateral cervical spine noted an anterior head carriage with the dens 21 mm anterior to the C7 body. An interruption in Georges line was noted at C2-3 and C3-4. A cervical kyphosis was noted from C3-6 and the atlas angle at 1 degree. The lateral lumbar noted a slight anterior gravity line from L3 through the sacral base. A healed fracture was noted in the distal half of the sacrum giving the sacrum an irregular contour from S3-S5. Her films were graded as a phase I for subluxation-degeneration. Vertebral subluxation complex was noted. Kinesiopathology was noted to be moderate, neuropathophysiology was noted to be moderate, myopathology was noted to be moderate and histopathology was noted to be mild.

Case Two

A 36 year old, 5'6" 143 pound Caucasian female presented with the chief concern of infertility. Her history involved a fully blocked left fallopian tube and a partially blocked and damaged right fallopian tube. She noted a 9 year history for high prolactin levels.

She had five years of dysmenorrhea which was worsening with a menstrual cycle which disappeared on the 3rd day and reemerged with bright red blood by the end of the fourth day. Stress caused this pattern to increase. She had been on Inserol for four months. She stated she had been under gynecological care for a number of years. Additional complaints were low back pain midline limited to the lumbar and sacral spine without radiation into the legs, abdominal discomfort with bloating and a constant *istich* across the right inguinal region. Her past history involved a motor vehicle accident 12 years prior while she was the driver, wearing a seatbelt when she was hit from the front left side and sustained left knee damage which required surgery.

Postural observation noted unleveling of the right shoulder girdle with scapular flaring, an increase in the thoracic kyphotic contour and a left laterally translated occiput.

Gross passive ROMs were limited in cervical extension by 10 percent with pain elicited to the right of C7. Cervical flexion caused a pull from C6-T2. Left lateral flexion showed a loss of motion from T5-10 with an overall reduction by 10 percent. Left Lumbar Kemps test caused pain at L4 on the left. All other active and passive spinal ranges of motion were within normal limits.

Deep tendon reflexes were within normal limits. Sensation to pinwheel in the upper and lower limbs were unremarkable. Resisted muscle strength tests were unremarkable in the upper limbs. Mild right psoas weakness was noted upon testing the legs. Right straight leg raising was limited at 80 degrees with a hypertonic hamstring. Knee to chest was stiff on the left and reduced by 10 percent on the right. Fabre Patrick test was reduced 30 and 20 percent on the left and right respectively.

Initial examination revealed evidence of Tonal changes with a negative left Derifield and positive right Cervical syndrome.

Muscular hypertonicities were noted in the gluteals and trapezius bilaterally.

Increased resistance and tone was noted bilaterally along the full spinal length of the paraspinal muscles.

Tenderness was noted with palpation to each side of the pubic symphysis and the right ASIS. The right inguinal ligament was also tender to palpation.

Thermography and Surface EMG were performed according to the protocol of use by the Insight 7000 subluxation station. Mild increase in tone was noted with asymmetry at the right cervico-thoracic region and left lower thoracic region. Asymmetry was mildly increased in the right lumbar region. Thermography noted multiple levels of mild involvement (within one standard deviation) in the upper cervical mid thoracic and upper to mid lumbar region.

Segmental palpation noted aberrant joint play at the left occiput, atlas and axis, bilateral C7, T5, T11-L3, sacrum, and right coccyx. Additionally sensitivity and tenderness was noted with palpation at L2-3 on the right.

X-rays were taken in the weight bearing position of an AP full spine, Lateral cervical and Lateral lumbar.

The AP noted a mild 7-degree convex right curve from T10-L3 with the apex at L1. As a result L1-L4 vertebral bodies were superior to the left and T9-12 were superior on the right. A 5-degree translation was noted from C4 on the left to T4 on the right.

Spinous process rotation to the right was noted at C4-5 and T2-3. Innominate length was 213 on the left and 215 mm on the right. Early lipping and spurring was noted bilateral at L3-4 endplates. The lateral cervical demonstrated a general reduction in lordosis. The occiput was PS relative to atlas. Early osteophytic growth was noted at the endplates of C5-6 both anterior and posterior. Lateral lumbar noted lipping and osteophytic growth at L2-4 anterior. Mild lipping and osteophytic growth was noted anterior and posterior at L4-5 and to a greater extent at L5-sacrum. A reduced disc height was noted at L5-sacrum. L4 was mildly posterior relative to L5. A moderate reduction in the IVF was noted at L5-sacrum and mild IVF reduction at L4-5. Her films were graded as a late phase I - early phase II for subluxation-degeneration. Vertebral subluxation complex was noted. Kinesiopathology, neuropathophysiology and myopathology components were felt to be moderate. Histopathology components at mild.

Chiropractic Care and Outcome:

Case One:

A report of findings was delivered and consent was given for care. The patient was placed on a course of chiropractic

care of 3 visits per week for 4 weeks with the plan to reassess after 12 visits. The protocol for Torque Release Technique was utilized with the delivery of the adjustment made by the Integrator. On each visit, the patient was evaluated from the prone position and adjusted according to the TRT protocol (see figures 1 and 2). Segments noted as adjusted throughout the course of the initial twelve visits but not on each visit were: C0, C1, C2, right sacrum, T2, T3, T4, L3, L5 left and right innominate, C5, and T8.

The patient was irregular with her frequency of care. As her insomnia was occurring, her medical physician gave her a prescription for sleeping pills which she did not fill.

She also had surgery for breast adhesion release after her 11th visit. She was re-evaluated at the 12th visit. An increase in her thermal readings and surface EMG tone was noted but palpation findings were improving for tissue compliance, less resistance and improved vertebral segmental motion.

At this time her chiropractic care was reduced to twice per week for six weeks. Her attendance for adjustments was irregular with a full month interruption in chiropractic care. TRT protocols indicated adjustments at similar levels with the addition of

Figure 1: TRT's 14 Indicators of spinal subluxation.

These can be separated into observational findings and palpatory findings. These were used as indicators to adjust. For the significance and priority of the adjustment protocol, refer to Dr. J. Holderis work⁶

PALPATION: includes scanning superficially for changes in skin drag, heat, tension, turgor, resistance, imbalance or asymmetry; static segmental and motion palpation assessment; changes in tissue tone or congestion in tissue on palpation.

FUNCTIONAL LEG LENGTH INEQUALITY (LLI):

ABDUCTOR TENDENCY / ADDUCTOR RESISTANCE:

FOOT FLARE: EVERSION / INVERSION

FOOT PRONATION / SUPINATION

HEEL CORD TENSION / ACHILLES TENSION

ABNORMAL BREATHING PATTERNS: compartmentalized breathing, noting where breathing is limited or restricted

INAPPROPRIATE SUSTAINED PATTERNS OF PARASPINAL MUSCLE CONTRACTIONS/POSITIVE JUMP SIGN/ MYOIRRITABILITY/EMG CHANGES

EVIDENCE OF CONGESTIVE TISSUE TONE:

POSTURAL FAULTS (STANDING/SITTING/PRONE): The inability to maintain or adapt to space and gravity in an appropriate posture

CERVICAL SYNDROME TEST:

BILATERAL CERVICAL SYNDROME TEST:

DERIFIELD TEST:

ABNORMAL HEAT/ENERGY RADIATION FROM THE BODY (example: thermography, thermograph, neurocalometer, tissue humidity changes)

one visit an adjustment was indicated at T12 and on another at L2.

Two weeks prior to the second re-assessment she had an influenza vaccination. Subsequently, she had symptoms of vertigo, a right-sided torticollis and tonsillitis for which she was given penicillin.

At this assessment her gross passive cervical, thoracic and lumbar spinal ROMs were within normal limits. However, lumbar spinal extension was tender at end range in the lower lumbar spine and right lateral bending demonstrated reduction in lower thoracic motion.

Postural changes noted a shift to a left superior occiput and shoulder. The pelvis was level. Testing of muscle strength noted mild weakness with pain in the right deltoid where the inoculation was administered. Sensation to pinwheel noted increased sensitivity along the full right side upper and lower limb.

Muscular hypertonicity was noted in the trapezius, supraspinatus and levator scapular bilateral. Thermography noted an increase in the signal at the upper cervical spine and L5. The surface EMG noted improvement in symmetry and reduction (calming) in signal throughout.

As the underlying joint function was improving, the patient was given low back stabilizing exercises and cervico-thoracic stretching to be performed daily. Her care was scheduled at two times per week but the patient only attended weekly.

Four weeks after her comparative examination, the patient noted she was six weeks pregnant. Her care continued throughout the pregnancy with a complication of vaginal spotting be-

tween 8 through to 11 weeks gestation. She was medically monitored, felt to be stable and not treated.

An exacerbation of low back pain and a worsening of insomnia was mentioned by the patient after traveling for six weeks. Upon return, she commented on a correlation between missing her chiropractic appointments and a worsening of her inability to sleep and back pain. Spinal palpation and TRT findings noted increased spinal stress so she was recommended a temporary increase in her frequency of care to three times per week which she maintained for two weeks. Her subsequent frequency of care she undertook was approximately once per week.

Case Two:

A report of findings was given to the patient with a course of care recommended. Consent was given to begin and chiropractic care was delivered at a frequency of twice per week for six weeks utilizing the protocol for Torque Release Technique with the delivery of the adjustment made by the Integrator. On each visit, the patient was evaluated from the prone position and adjusted with the TRT protocol using the Integrator (see figures 1 and 2).

Over the course of the initial twelve visits the following segments were indicated to adjust on varying visits: C0, C1, C2, C5, T2, L2, L3, L4, S2, S3, coccyx and sphenoid.

She had a progress reassessment at the 12th visit. SEMG noted a calming in her muscle tone with less asymmetry. Her Thermography noted calming in her cervical spine, a similar pattern in her thoracic spine and an increase in signal at the sacrum. A low back program of exercises was instigated at this time with a continuation in the frequency of two visits per week for a further two weeks, then she was reduced to weekly appointments.

Two weeks later she became pregnant. Her care continued for a further 5 weeks then the patient self-discharged. On follow-up she had a normal pregnancy which was taken to term with delivery.

Discussion:

Infertility medical management may involve treatments at many levels. This may range from medications such as hormonal treatments and ovulation stimulation to surgeries involving parts of the reproductive system such as reconstructive surgeries. Other technologies may be utilized such as intrauterine insemination, in vitro fertilization, egg/sperm donation and surrogacy.

If infertility was recognized as an end-stage outcome, as a result of aberrant function in the interplay of one or many variables, the causes of infertility may be simplistically broken down into three main groups. Utilizing the classic 3T's (trauma, toxicity and thoughts) as a reference, infertility may be an end result from numerous risk factors such as any condition which may change the bodies structure and thus function. Examples of effects from trauma causing structural and functional changes might be pelvic organ position/alignment, inflammatory diseases with scarring, other physical obstruction of any part of the reproductive tract, congenital anomalies, weight and changes in neurological function.

Figure 2: How adjustments were performed:

According to TRT protocol an adjustment is performed only on the segments which deem a response by performing a pre-check and a post check.

The order of adjustment was made dependent on the highest priority indicator present at the time of the visit presentation.

Once an indicator was found, the corresponding spinal segment was checked to note if a pressure test caused a physiological response. This pressure check was performed manually with the distal phalanx of the index finger contacting a spinal segment.

Prior to each adjustment, the indicator used in determining the segment to adjust was re-visited to observe if a physiological response was made towards normal. If a partial response was made, the procedure was repeated at other segments until the appropriate balance of the indicator occurred or another indicator was viewed as higher priority and the corresponding segments checked.

Fine tuning was performed to note the contact point on the vertebrae (spinous process, lateral mass, articular pillar for the appropriate vector and if indicated the need for torque as indicated.

Once the indicator, segment, vector(s) and torque were found, the Integrator was set to deliver the adjustment.

Once the adjustment was delivered, the indicator was re-visited to note its amelioration.

As per TRT protocols, the legs were pumped three times and the above procedure was repeated as indicated. This was performed usually two to three times in a visit.

As per TRT protocol, care was taken to maintain the non-linear nature of the technique by avoiding adjusting the same segments in the same manner (vector, contact and order) greater than three times in a row.

Examples of effects by changing the bodies toxicity or chemistry might be from any change in the hormonal balance of the body, inadequate diet, concomitant diseases such as autoimmune diseases and pro-inflammatory states, presence of sexually transmitted diseases, pelvic inflammatory disease, endometriosis, fibroids, lifestyle habits such as smoking, alcohol, use of certain drugs, chemical exposure and age.

Examples of thoughts would best be represented by the cumulative effects on the body, in particular on the nervous system by the general adaptive response as discussed by Hans Selye.¹²

Chiropractic as a vitalistic profession would recognize the interplay between the three as an impact in one may dynamically alter or change the effect in another system as all systems are interdependent. LeBouef-Yde noted changes reported upon improved non-musculoskeletal symptoms subsequent to chiropractic care.⁷

Masarsky reviewed the impact of chiropractic care via somatovisceral effects.⁸

Sato has noted the impact of somatosensory input on autonomic functions.⁹

Burns reported the effects of subluxations induced in the cervical and lumbar spine upon the course of pregnancy as noted in rats, rabbits, guinea pigs and cats. It was noted, ifetal development is subject to the influence of practically every factor which effects maternal physiology, although in most instances it is not possible to trace the relation between cause and effect. In this paper, it was noted that animals who were experimentally subluxated, could not conceive, were unable to maintain a viable pregnancy or had congenital abnormalities when compared to non-subluxated mammals.¹⁰

This suggests that there is a profound relationship between aberrant spinal function with functional implications.

These two cases are of interest as other anecdotal cases are present in the chiropractic literature.^{1,2,3} It is postulated that by improving the biomechanical integrity of the spine and changing the facilitation of the nervous system, a restoration of homeostasis can occur.

Both cases are interesting in that one presented with the chief complaint of low back pain while the other presented with the concern of infertility and during questioning it was revealed

that she had a history of low back pain. Both had aberrant spinal function detected at various levels of their spine. Both had experienced a history of trauma. Both women were 35 or over. Both had been trying to conceive for greater than one year. Both were adjusted using TRT protocols with the Integrator.

The first case was a challenge as the patient was experiencing severe levels of family stress which would have impacted her response to care. In addition, her situation necessitated travel which interfered with her schedule of care. Even so, this case demonstrated improvements within the parameters of seeing positive physiological changes at her visits.

Both cases had evidence of changes in Tone as defined by DD Palmer for which the tone of the tissue is reflected in the state of health of the tissue. Life is the expression of tone. In that sentence is the basic principle of chiropractic. Tone is the normal degree of nerve tension. Tone is expressed in functions by normal elasticity, activity, strength and excitability of the various organs, as observed in a state of health.

Consequently, the cause of disease is any variation in tone.¹¹

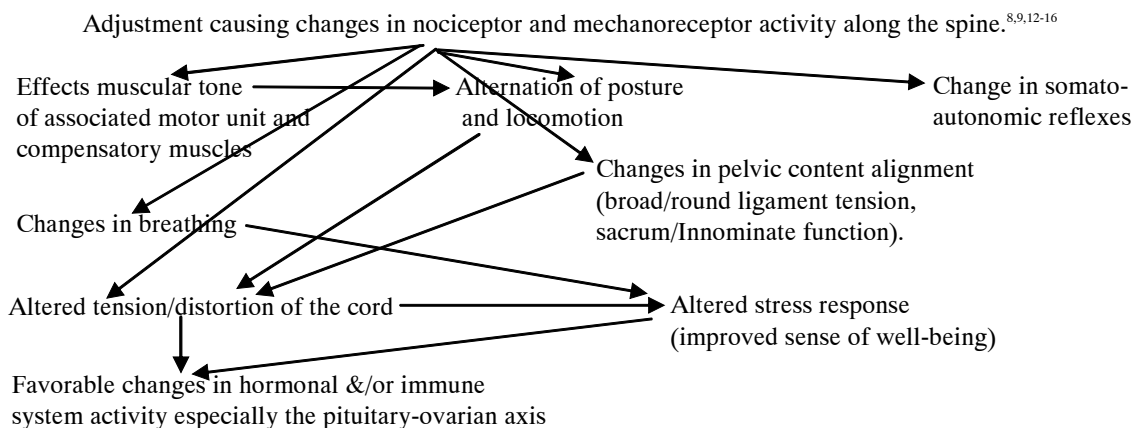
As interpreted by this author, poor adaptation of a person to their environment due to an inability or loss in the ability to comprehend and respond to their surroundings would be a consequence of altered Tone. This change in Tone could manifest in many ways, but ultimately it alters the ability to self-regulate and express.

It is postulated that the changes observed with each patient's re-assessment and the improvement in spinal and neural integrity caused changes to occur in far reaching ways. It is important to note that this chiropractic care was not based as a treatment for the symptoms such as low back pain or infertility but to improve the spinal-neurological function and health through the reduction of subluxations.

Conclusion:

Coincidentally, these cases are clinically relevant as both women were referred to chiropractic care by a friend who heard of results with becoming pregnant through chiropractic care. Both cases had a history of trauma. Both had evidence of subluxations for which chiropractic care was instituted. Upon reduction of the vertebral subluxation there was an improvement in spinal-neural function which appeared to have an im-

Figure 3: Postulated mechanisms observed with a potential impact on fertility



pact on the reproductive system through various postulated mechanisms.

Anecdotally, this author notes discussions within the profession by colleagues at seminars who have noted similar results in clinical practice. There is a paucity of published research in this area. Further research needs to be performed to validate the outcome on chiropractic care through the reduction of vertebral subluxations and improvement in bodily function on end stage dis-ease and overall health status.

References:

1. McNabb B. The Restoration of Female fertility in Response to Chiropractic Treatment. Proceedings of the national Conference on Chiropractic and Pediatrics. ICA 1110 N Glebe Rd. Arlington, VA 22201. 1994:55-64
2. Webster LL. Inability to conceive. Two case histories from the files of Larry Webster. International Chiropractic Pediatric Association Newsletter. Nov. 1995
3. Vilan, R. The Role of Chiropractic Care in the Resolution of Chronic Migraine Headaches and Infertility: A Case Study. Original Paper Presentation. Annual Conference on Chiropractic and Pediatrics. ICA 1110 N Glebe Rd. Arlington, VA 22201. November 22-24, 2002
4. Association of Chiropractic Colleges: Issues in chiropractic. Position Statement #1. The ACC Chiropractic Paradigm, Chicago, July 1996, Association of Chiropractic Colleges.
5. Palmer DD, The Science, Art and Philosophy of Chiropractic, 1910 : 364
6. Holder. JM. Torque Release Technique Seminar Notes. Miami FL 1997
7. LeBouef-Yde, Axen I, et al. The types and frequencies of improved non-musculoskeletal Symptoms reported after chiropractic spinal manipulative therapy. JMPT 1999;22:559-64
8. Masarsky CS and Todres-Masarsky. Somato-visceral aspects of Chiropractic: An evidence-based approach. Philadelphia,PA: Churchill Livingstone, 2001:1-5, 37-49,109-138
9. Sato A, Sato y, Schmidt RF. The impact of somatosensory input on autonomic functions. Reviews of Physiology, Biochemistry and Pharmacology. Vol 130. Berlin: Springer-Verlag;1997.
10. Burns L. Vertebral Lesions and the Course of Pregnancy in Animals. JAOA, 1923;Vol23(3)
11. Palmer DD, The Science, Art and Philosophy of Chiropractic, Portland Oregon. Portland Printing House Co.:1910 :7
12. Selye H. Stress without Distress. Penguin Books of Canada Ltd. 1981
13. Korr IM. Sustained sympatheticotonia as a factor in disease. In Korr IM editor: The neurobiologic mechanisms in manipulative therapy, NY: Plenum Press, 1977
14. Breig A. Adverse mechanical cord tension in the central nervous system. New York. John Wiley and Sons, 1978:
15. Kent C. Models of Vertebral Subluxation: A review: JVSR. August 1996;1(1):11-17
16. Boone, WR, Dobson GJ. A proposed Vertebral Subluxation Model Reflecting Traditional Concepts and Recent Advances in Health and Science. JVSR August 1996;1(1):19-30